

METHODS

Management of perforated peripheral ulcerative keratitis (PUK-Mooren's ulcer) with iris prolapse study in two cases

Sujit Kumar Biswas^{1*}, A. S. M. Mahbubul Alam¹, Soma Rani Roy² and Abdul Matin Bhuyan¹

¹Department of Cornea, Chittagong Eye Infirmary and Training Complex, Chattogram, Bangladesh

²Chittagong Eye Infirmary and Training Complex, Chattogram, Bangladesh

***Correspondence:**

Sujit Kumar Biswas,
dr.sujitkumar2020@gmail.com

Received: 28 March 2023; **Accepted:** 11 April 2023; **Published:** 19 May 2023

Aim: The aim of this study was to describe the management of two cases of perforated peripheral ulcerative keratitis (PUK-Mooren's ulcer) with iris prolapse by using dried sclero-corneal patch graft and subsequently replacing donor sclero-corneal patch graft.

Methods: After sectoral conjunctival resection, ulcer margin excision, and prolapsed iris excision, preserved dried sclero-corneal tissue is fashioned, and patch grafting is done as an emergency. After getting the donor sclero-corneal rim, it was again fashioned (matching the size and removal of Descemet's membrane) and replaced the dried scleral patch graft followed by a bandage contact lens.

Results: Eleven to 16 months after their initial evaluation, these patients still had some useful vision and self-satisfaction.

Conclusion: A dried sclera-corneal patch graft could be a satisfactory option in the temporary management of perforated PUK with iris prolapse until donor tissue is available. This patch graft prevents hypotony, posterior synechiae, and secondary glaucoma.

Keywords: peripheral ulcerative keratitis, patch graft, dried sclero-corneal tissue, Mooren's ulcer

Introduction

Peripheral keratitis (PUK-Mooren's ulcer) is specified by its progression first circumferentially and then centrally (1). Albert Mooren, who first described this disease that has a unilateral or bilateral involvement (1–3), PUK also has an infective or a non-infective (immunologic) etiology. Topical medication with corticosteroids gives a good response in the early phase of this disease. However, corneal perforation may occur in advanced stages and need urgent surgical intervention for tectonic support of the eyeball and visual rehabilitation (4). Such surgical treatment of small (less than 2 mm) perforating PUK includes conjunctival advancement flap, application of cyanoacrylate and fibrin glue, and multilayered amniotic membrane transplantation. In larger perforation (more than 2 mm), we need a corneal patch graft, scleral patch graft, and lamellar and penetrating keratoplasty (4). In the absence of available donor tissue, we need to seal

the perforation with another easy procedure like preserving dried sclero-corneal tissue to save the eyeball.

In these two cases, the perforations were more than 4 mm, and in the absence of donor tissue, we used dried, preserved sclero-corneal tissue as temporary management to maintain the shape of the globe and prevent perforation-related complications. Later, we replaced the dried sclero-corneal tissue with fresh donor tissue.

Research elaboration: Case presentation

Case 1

A 45-year-old woman complains of a painful vision reduction with redness and watering in her right eye for the last 2 weeks. The patient was diagnosed clinically with perforated

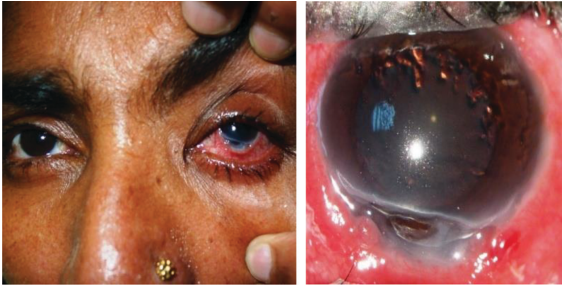

FIGURE 1 | Presentation with perforation along with iris prolapse.

PUK with iris prolapse (**Figure 1**). The patient was non-diabetic and normotensive. Scrapping the ulcer margin was done for microscopic examination to rule out any associated infection. The microscopic examination revealed no organisms. As an emergency, the patient was advised to undergo a dried sclero-corneal patch graft, as donor tissue was not available at that time. On the same day, the patient underwent surgical intervention: resection of the surrounding conjunctiva, excision of the necrotic ulcer margin, repositioning of the prolapsed iris, and a dried sclero-corneal patch graft under local anesthesia, followed by bandage contact lens application (**Figure 2**). The patient was treated postoperatively with atropine 1 eye drop 8 h, moxifloxacin 0.5 eye drop 4 h, and dexamethasone 0.1% eye drop 4 h in her left eye and advised for review after 7 days along with some systemic investigations such as CBC, ESR, RA factor, VDRL, TPHA, urinalysis, and chest X-ray. On follow-up, all investigations were within normal limits. After a month, the eyeball showed stability as there was decreased ciliary congestion, quiet anterior chamber (**Figure 3**) dried tissue was replaced by a donor sclero-corneal patch graft along with a bandage contact lens. The patient was treated with atropine 1 eye drop 8 h, moxifloxacin eye drops 0.5 4 h, and dexamethasone eye drops 0.1 4 h per day. After a month, the bandage contact lens was removed, and corticosteroid drops were tapered over the next 2 months and continued as a once-daily dose. The graft was quiet healthy with intact all sutures with minimum congestion and round-reacting pupil and quiet anterior chamber (**Figure 4**). Digitally, IOP was measured on each visit. Sixteen-month follow-up shows that the patient still has some useful vision (6/36) and satisfaction (**Figure 5**).

Case 2

A 30-year-old man complains of a marked reduction of vision with pain in his right eye associated with redness and watering for the last 10 days. The patient was diagnosed with perforated PUK with iris prolapse (**Figure 6**). There was no history of systemic disease. The scraping of the ulcer margin showed no infection. As per advice, the patient underwent surgical intervention: resection of the

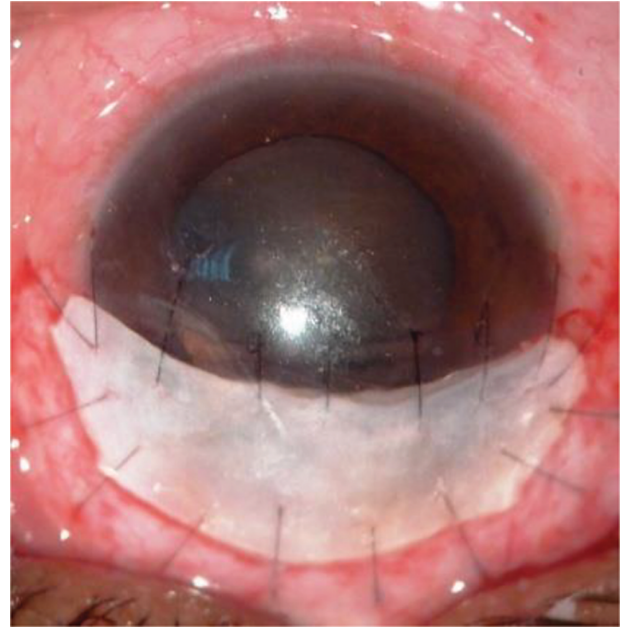


FIGURE 2 | Intraoperative view (dried sclero-corneal patch graft).

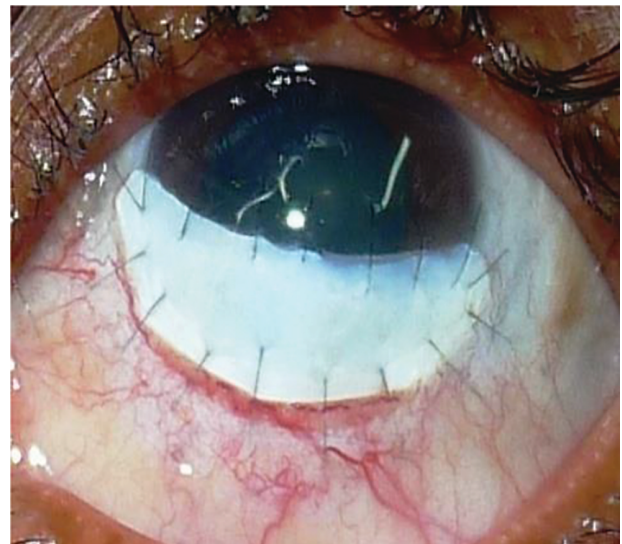


FIGURE 3 | One month postoperative (dried sclero-corneal patch graft).

surrounding conjunctiva, excision of the necrotic ulcer margin, resection of the prolapsed iris, and a dried sclero-corneal patch graft followed by bandage contact lens application under local anesthesia (**Figure 7**). The patient was treated postoperatively with atropine 1 eye drop 8 h, moxifloxacin 0.5 eye drop 4 h, and dexamethasone 0.1% eye drop 4 h in his right eye and advised for review after 7 days along with some systemic investigations. All systemic investigations (CBC, ESR, RA factor, VDRL, TPHA, urinalysis, and X-ray chest) were normal. Two weeks postoperatively, the graft was still intact (**Figure 8**), but the graft became started to melt at 1-month postoperative

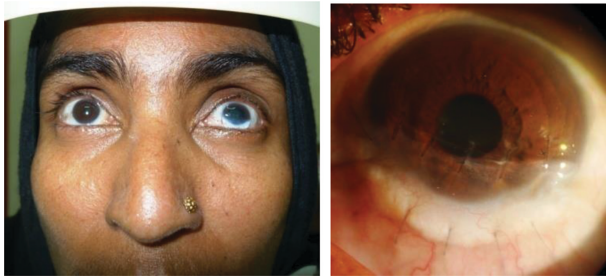

FIGURE 4 | Three months postoperative after fresh donor sclero-corneal patch graft.

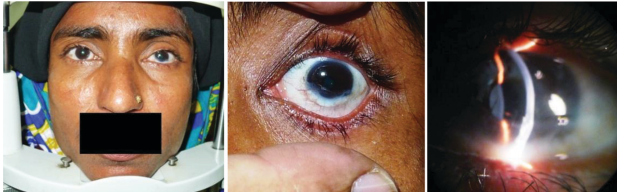

FIGURE 5 | Sixteen months postoperative status showed quiet eye with some useful vision (6/36).

follow-up (**Figure 9**). Immediately, the melting graft was replaced by donor sclero-corneal tissue along with a bandage contact lens (**Figure 10**). The patient was again treated with atropine 1 eye drop 8 h, moxifloxacin 0.5 eye drop 4 h, and dexamethasone 0.1 eye drop 4 h per day in his right eye. After a month of graft replacement, the bandage contact lens was removed, and a small epithelial defect was found over the graft (**Figure 11**), which was healed subsequently without any complications (**Figure 12**). Corticosteroid drops tapered over the next 2 months and continued as a once-daily dose. Digitally, IOP was measured on each visit. After an 11-month follow-up, there was a satisfactory outcome with the preservation of some vision (3/60) (**Figure 13**).

Discussion

Mooren's ulcer is an idiopathic keratitis involving the peripheral cornea that is painful in nature with an overhanging central edge and progresses circumferentially and then centrally as the disease becomes advanced (5). This disease has no associated scleritis. Any age group of either gender might be affected, but most of the patients are between 40 and 70 years old. Interpalpebral limbus and peripheral corneal ulceration with unilateral involvement are more common (5). Most of the PUK (Mooren's ulcer) heals spontaneously (6). Perforation is less common but most dangerously associated with endophthalmitis, even phthisis bulbi (6). The pathogenesis involves adjacent conjunctival tissue producing collagenase in the absence of circulating suppressor T-lymphocytes (7, 8). Gottsch et al. also demonstrated autoantibodies against corneal stromal tissue in response to the hepatitis C virus, resulting in

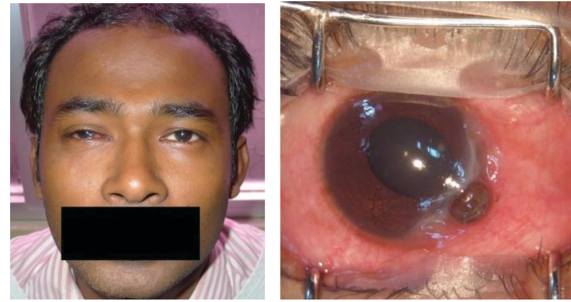

FIGURE 6 | At presentation.

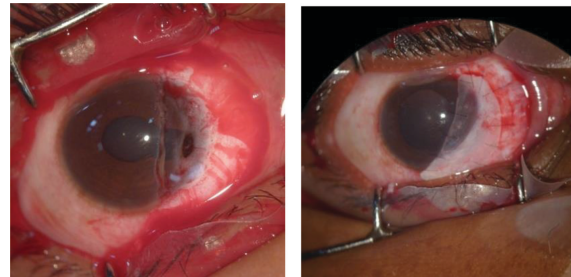


FIGURE 7 | Intraoperative, resection of conjunctiva and ulcer margin excision and dried sclero-corneal patch graft.

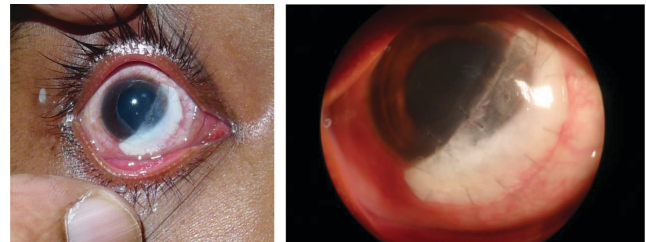

FIGURE 8 | Two weeks postoperative view. Dried sclero-corneal tissue is still intact.

peripheral corneal stromal destruction (9). Conjunctival resection is done when topical corticosteroids fail to produce a response. Systemic immunosuppressive agents such as methotrexate and cyclosporine are necessary when both of them are not responding (10–12). Peritomy with cryotherapy was suggested by Aviel in Blantyre, Malawi, in 1972 (13).

Untreated cases result in severe irregular astigmatism, cataract formation, secondary bacterial infection, secondary glaucoma, and perforation even with minor trauma. Perforation is the most dangerous complication that requires urgent surgical management for visual rehabilitation. Cyanoacrylate glue can be used to seal less than 2 mm of perforation in the cornea. But larger perforations need a patch graft or keratoplasty (5). Other tissues can be used, such as a multilayer amniotic membrane graft, conjunctival hooding, Tennon's patch graft (from the same or fellow eye), lamellar scleral patch grafts, autologous fascia lata, and autologous oral mucous membrane (14, 15).

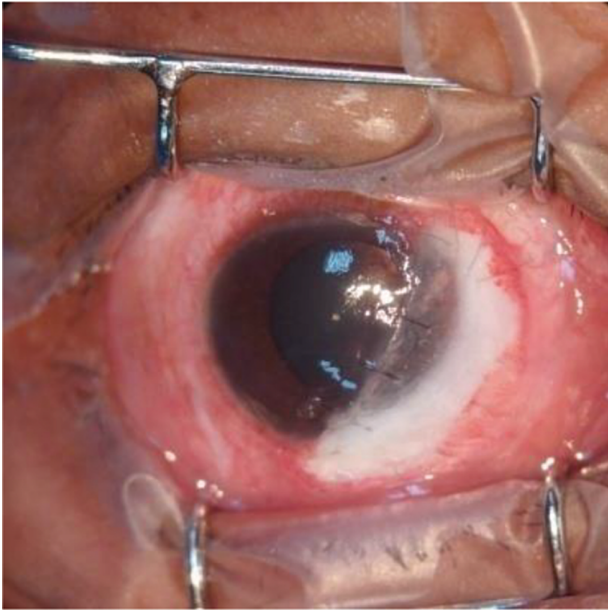


FIGURE 9 | One month postoperative view. Dried sclero-corneal tissue became melting.

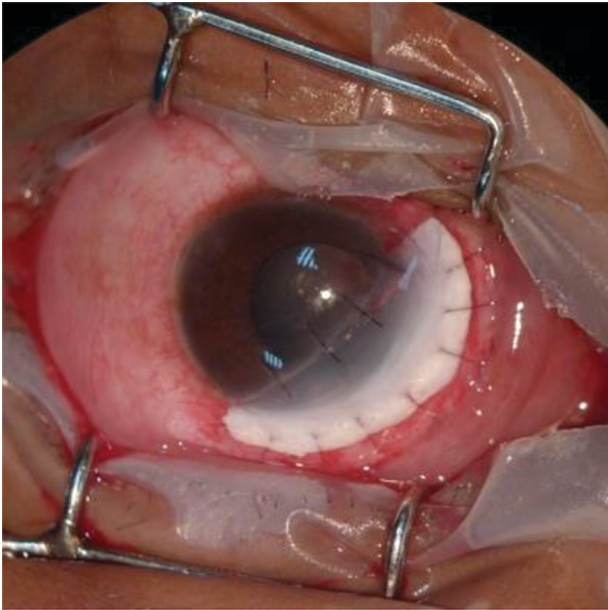


FIGURE 10 | Dried melting tissue is replaced by fresh donor sclero-corneal tissue.

Here, we used a dried sclero-corneal crescentic patch graft as an emergency basis because, at that time, donor cornea was not available. We prepared dried sclero-corneal tissue from the remaining sclero-corneal rim of donor tissue after using the central corneal button for keratoplasty. The tissue rim is cleaned, heat dried, packaged, sterilized by ethylene oxide, and then preserved at room temperature for a year. Four to five millimeters of the conjunctiva was resected posterior to the limbus, and 2 mm of the conjunctiva was resected on both sides of the ulcer. Overhanging ulcer margins are

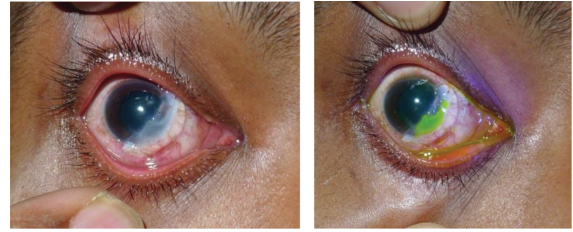

FIGURE 11 | One month after tissue replacement. Some epithelial defects are still there after the removal of the bandage contact lens.

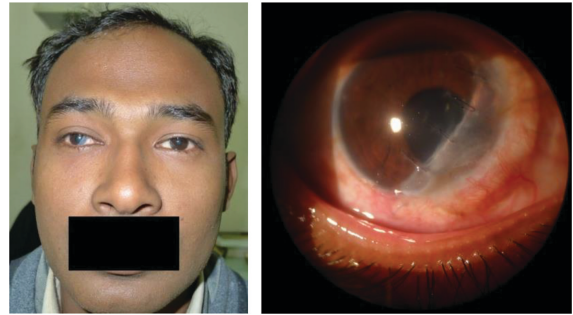


FIGURE 12 | Two months after tissue replacement.

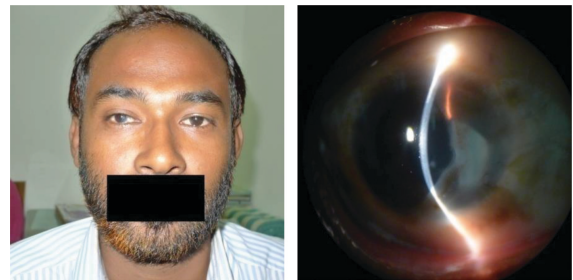

FIGURE 13 | Eleven months after tissue replacement (quiet eye with VA 3/60).

excised during a dried tissue patch graft. The prolapsed iris appeared to be fresh in the first case, and it was repositioned; in the second case, the prolapsed iris tissue was excised. Postoperatively, we used topical corticosteroids. In these two cases, we replace the dried tissue with fresh tissue after getting the donor cornea. Postoperatively, we used corticosteroids for 1 month, tapered over the next 2 months, and continued with a once-daily dose. The intraocular pressure was normal in each follow-up visit. After a year, the grafted eyes showed a stable condition, and patients were advised to follow up six months later.

Conclusion

A dried sclera-corneal patch graft could be a satisfactory option in the temporary management of large corneal perforations until donor corneal tissue is available. This patch graft prevents hypotony, posterior synechiae, and secondary glaucoma.

Author contributions

SB: concept, design, data analysis, and the manuscript preparation. AM: literature search and the manuscript editing. SR: manuscript the review and grammatical correction. AB: literature the review.

Acknowledgments

We thank to Dr. Ahmedur Rahman Research Center.

References

1. Sangwan V, Zafirakis P, Foster C. Moore's ulcer: current concepts in management. *Indian J Ophthalmol.* (1997) 45:7–17.
2. Alhassan M, Rabiu M, Agbabiaka I. Interventions for Moore's ulcer. *Cochrane Database Syst Rev.* (2011) 1:CD006131.
3. Chow C, Foster C. Moore's ulcer. *Int Ophthalmol Clin.* (1996) 36:1–13.
4. Sabhapandit S, Murthy I, Sharma N, Sangwan V. Surgical management of peripheral ulcerative keratitis: update on surgical techniques and their outcome. *Clin Ophthalmol.* (2023) 16:3547–57.
5. Prashant G, Virender S. Moore Ulcer. In: Krachmer JH, Mannis MJ, Holland EJ editors. *Cornea fundamentals, diagnosis, and management.* New York, NY: Elsevier (2011). p. 1149–53.
6. Srinivasan M, Zegans M, Zelefsky J, Kundu A, Lietman T, Whitcher J, et al. Clinical characteristics of Moore's ulcer in South India. *Br J Ophthalmol.* (2007) 91:570–5.
7. Brown S. Moore's ulcer histopathology and proteolytic enzymes of adjacent conjunctiva. *Br J Ophthalmol.* (1975) 59:6704.
8. Murray P, Rahi A. Pathogenesis of Moore's Ulcer: some new concepts. *Br J Ophthalmol.* (1984) 68:182–7.
9. Gottsch J, Liu S, Minkovitz J, Goodman D, Srinivasan M, Stark W. Autoimmunity to a cornea-associated stromal antigen in patients with Moore's ulcer. *Invest Ophthalmol Vis Sci.* (1995) 36:1541–7.
10. Ashar J, Mathur A, Sangwan V. Immunosuppression for Moore's Ulcer: evaluation of the Stepladder Approach—Topical, Oral, and Intravenous Immunosuppressive Agents. *Br J Ophthalmol.* (2013) 97:1391–4.
11. Kietzman B. Moore's ulcer in Nigeria. *Am J Ophthalmol.* (1968) 65:679–85.
12. Tandon R, Chawla B, Verma K, Sharma N, Titiyal J. Outcome of treatment of Moore's ulcer with topical cyclosporine at 2%. *Cornea.* (2008) 27:859–61.
13. Huang T, Wang Y, Ji J, Gao N, Chen J. Lamellar keratoplasty for the treatment of peripheral corneal perforation. *Zhonghua Yan Ke Za Zhi.* (2008) 44:104–10.
14. Amoni S. Acute purulent conjunctivitis in Nigerian children in Zaria. *J Pediatr Ophthalmol Strabismus.* (1979) 16:308–12.
15. Jayson M, Easty D. Ulceration of the cornea in rheumatoid arthritis. *Ann Rheum Dis.* (1977) 36:428–32.
16. Nnebe AU. Measles control in Nigeria: the case for a two-dose vaccine policy niger. *J Paediatr.* (2005) 32:41–5.
17. Mayo Clinic. *Rheumatoid arthritis vs. osteoarthritis Mayo Clinic Series.* Rochester, MN: Mayo Clinic (2021).